Irregular Bowel Habit

Dr. Md. Ashek Mahmud Ferdaus
FCPS (SURGERY), MS (Colorectal Surgery), FISCP(India).
Fellow International Society of Coloproctology.
Assistant Professor (Colorectal Surgery)
Mymensingh Medical College.

Normal bowel habit

Frequency-

- Varies from person to person.
- < 3/day and >3 days / week- normal.
- One hand there is constipation- <3 in a week.
- On the other hand diarrhea->3 bowel movements in a day.

Quantity-

- Varies from person to person.
- Should be < 200 grams daily
- Diarrhea -passing >200 grams or ml/ day.
- Weight- usually not considered in bowel regularity.

What are irregular bowel movements?

Irregular bowel movements- usually used to describe constipation.

At the extreme end of constipation is a complete lack of bowel movement- Obstipation.

- Technically it refers to obstructive constipation because even in severe constipation there is some stool passed eventually.

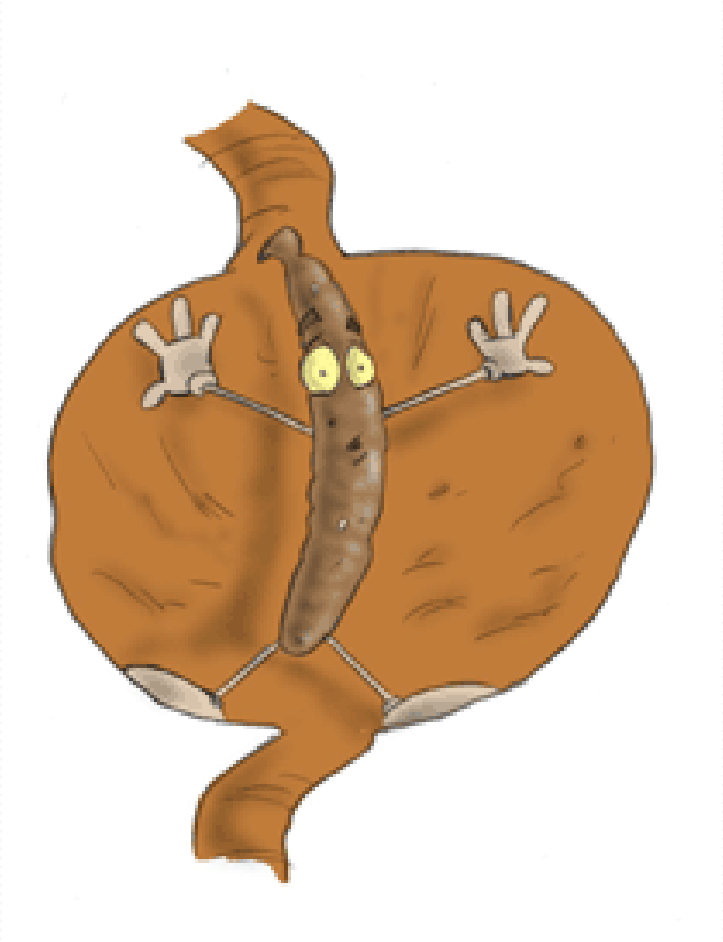

Constipation

Rome III criteria(Rome Committee in 2006)
for functional constipation

1. Must include ≥*2 of the following a :*
   - Straining during at least 25 % of defecations
   - Lumpy or hard stools in at least 25 % of defecations
   - Sense of incomplete evacuation for at least 25 % .
   - Sensation of anorectal obstruction/blockage for at least 25 % of defecations
   - Manual evacuation at least 25 % of defecations
   - <3 defecations / week

2. There are insufficient criteria for irritable bowel syndrome.
3. Loose stools rarely without the use of laxatives

- a Criteria fulfilled for the last 3 months with symptom onset at least 6 months prior to diagnosis

What is Obstipation?

Intractable constipation that has become refractory to cure or control is referred to as **obstipation**.

Obstipation (obstructive constipation)- loss of ability to pass stool or gas due to blockage or obstruction in the intestines.

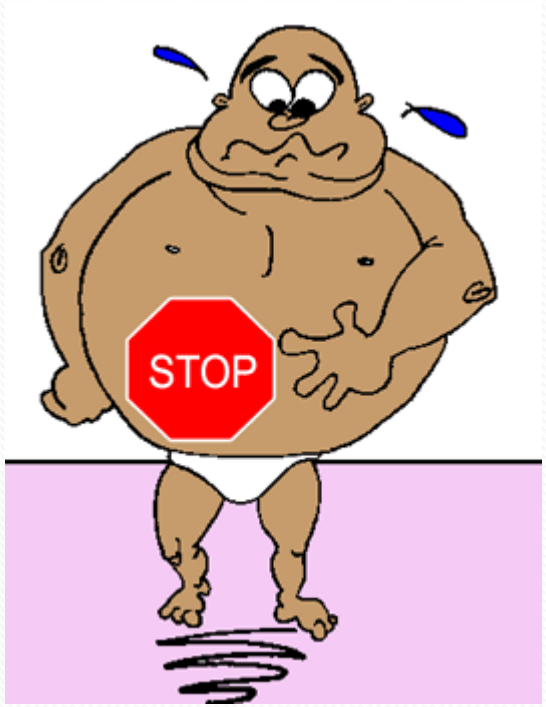

Factors associated with constipation

- **Lifestyle**
- **Medications**
- **Medical illness**
- *Endocrine / metabolic dysfunction*
- **Psychological**
- **Colonic structure/function**
- **Pelvic floor abnormality**

Lifestyle

- Inadequate fluid intake
- Inadequate fiber intake
- Inactivity
- Laxative abuse

Medications

- Opiates
- Anticholinergics
- Iron

Metabolic Causes of Constipation

- Hypothyroidism
- Diabetes mellitus
- Hypercalcemia
  - Depressive effect on autonomic nervous system
  - Smooth muscle hypotonicity
  - Dehydration
- Hypokalemia
- Uremia
- Heavy metal poisoning

Psychological

- Depression
- Anorexia
- Psychiatric illness
- Sexual abuse

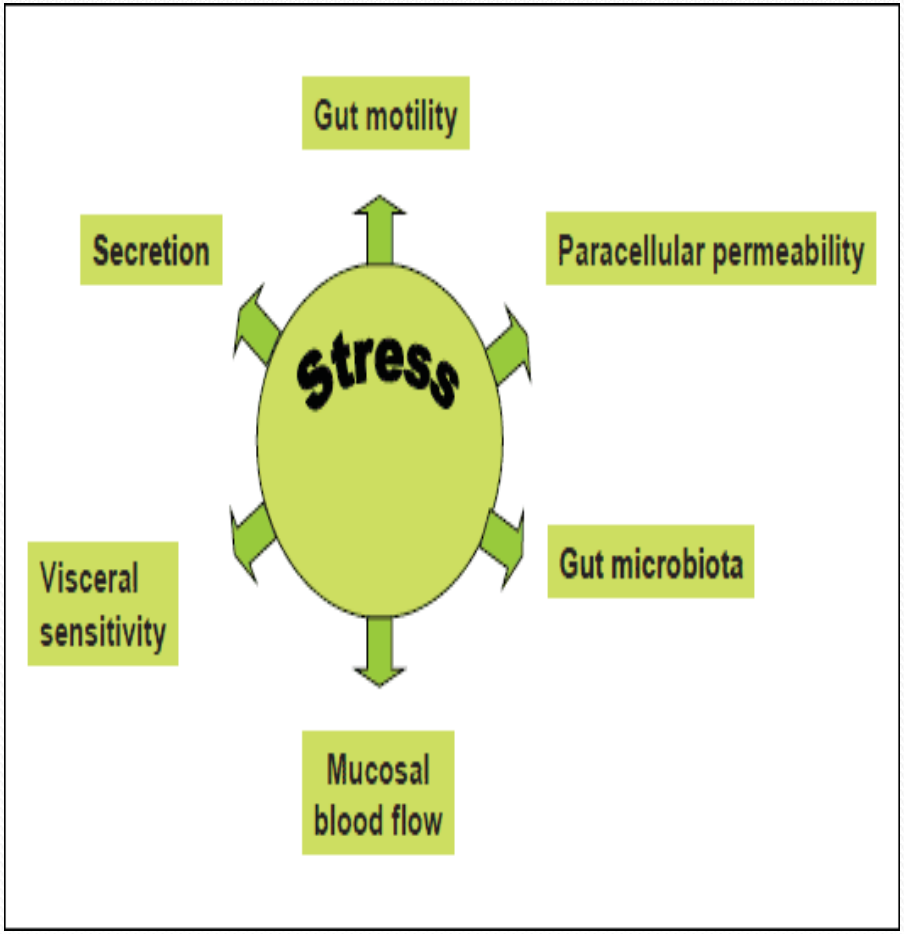

Colonic structure/function

- Cancer
- Crohn’s disease
- Irradiation
- Endometriosis
- Hirschsprung’s disease
- Chagas disease

Pelvic floor abnormality

- Nonrelaxing puborectalis
- Anal stenosis
- Rectocele/enterocoele/ sigmoidocele

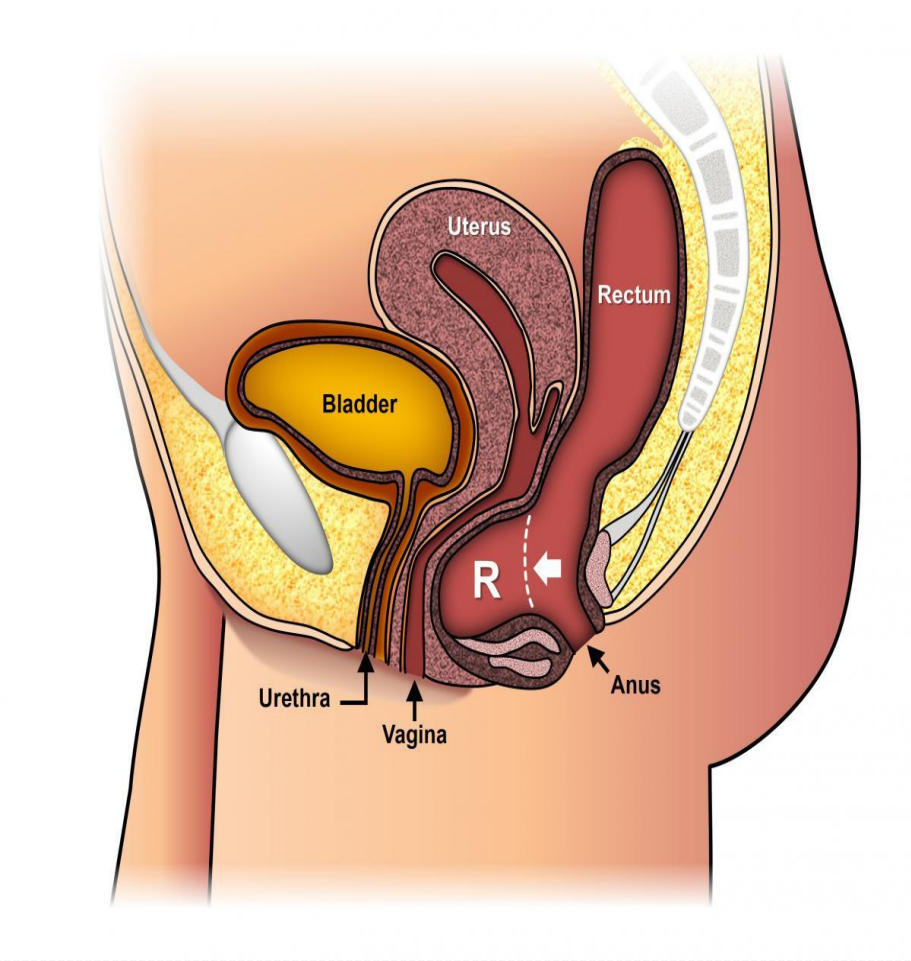

Constipation subtypes:

Slow transit or abdominal constipation-

- Motility disorder.
- Stool moves at a slow rate.
- Only colon is affected, while in others, other portions of the **GIT** may be affected.
- May not defecate for days to weeks at a time, despite using laxatives and enemas.

,

Normal transit / IBS -C-

- Functional disorder.
- Normal transit through the GIT.
- Stools are hard and defecation may be difficult.
- Additionally, patients may complaints of –
  - abdominal pain and
  - bloating that is relieved by defecation.

Pelvic constipation –

Lack of coordination of the pelvic floor.

Pathophysiology:

- rectal hyposensitivity, or
- constipation from impingement, such as-
  - rectocele, enterocele, & sigmoidocele.
  - full thickness rectal prolapse,
  - internal intussusception, and
  - SRUS.

Pelvic constipation results in-

- excessive straining,
- digital manipulation, and
- incomplete evacuation.

Each may occur in isolation or in various combinations.

History for patients with constipation

- Bowel habit frequency
- Stool consistency
- Onset and duration of symptoms
- Straining during defecation and need for manual assistance.
- Dietary history
- Exercise habits
- Laxative use
- Medication history
- Medical history
- Physical and sexual abuse history (20–30 %incidence).

Physical examination.

- Is often unremarkable.
- Abdominal examination may distention.
- Examination of the pelvic floor-
  - DRE - patient is asked to contract and relax the sphincter to assess-
    - Dyssynergia.
    - Rectocele
- Proctoscopy- anorectal mucosl abnormalities.
- Valsalva on the commode and the perineum should be studied for-
    - Perineal descent and
    - Prolapse of the rectum, bladder, or uterus.

Cellular Basis of Motility

- 2 layers of smooth muscle –
  - circular and longitudinal layers.
  - interconnected by gap junctions that allow electrical signals to spread in coordinated fashion.

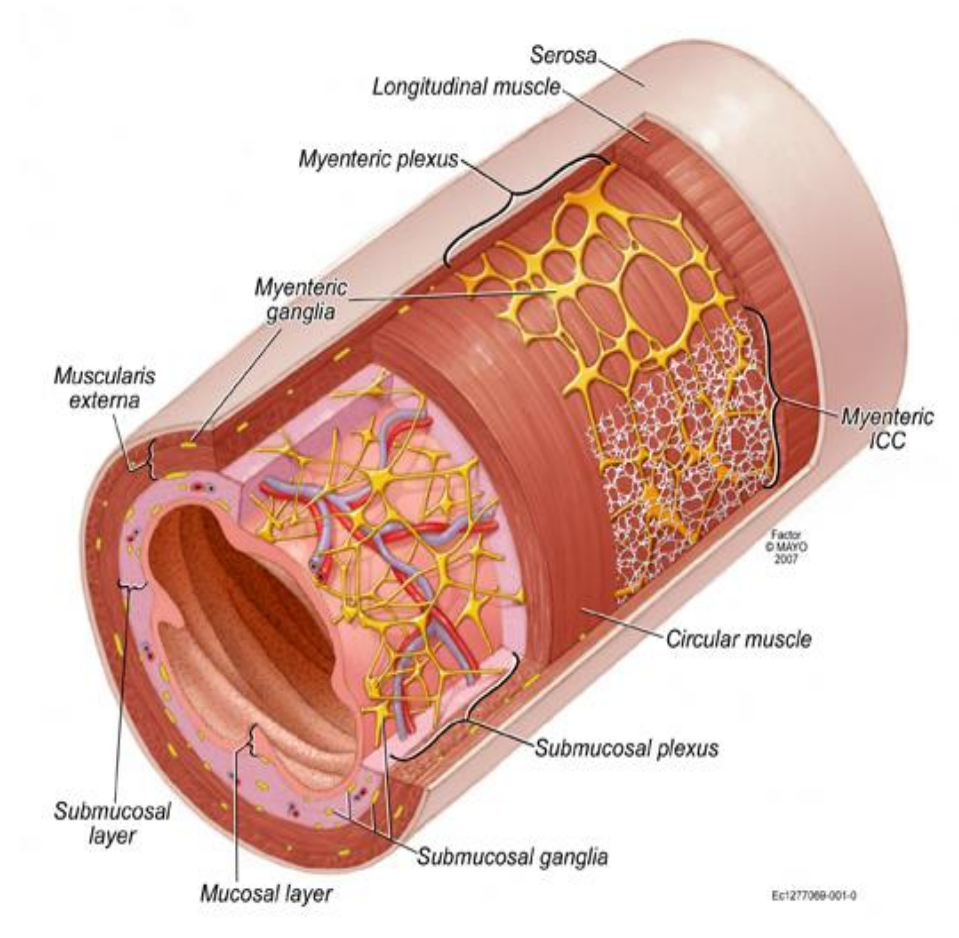

Interstitial cells of cajal

Colonic pacemaker cells-produce propulsive rhythmic activity.

- Occur in the submucosa and muscle layer.
- ICC-SM- slow repetitive waves.
- ICC-MP- Higher frequency oscillations .

But the slow waves from the ICC-SM seem to predominate.

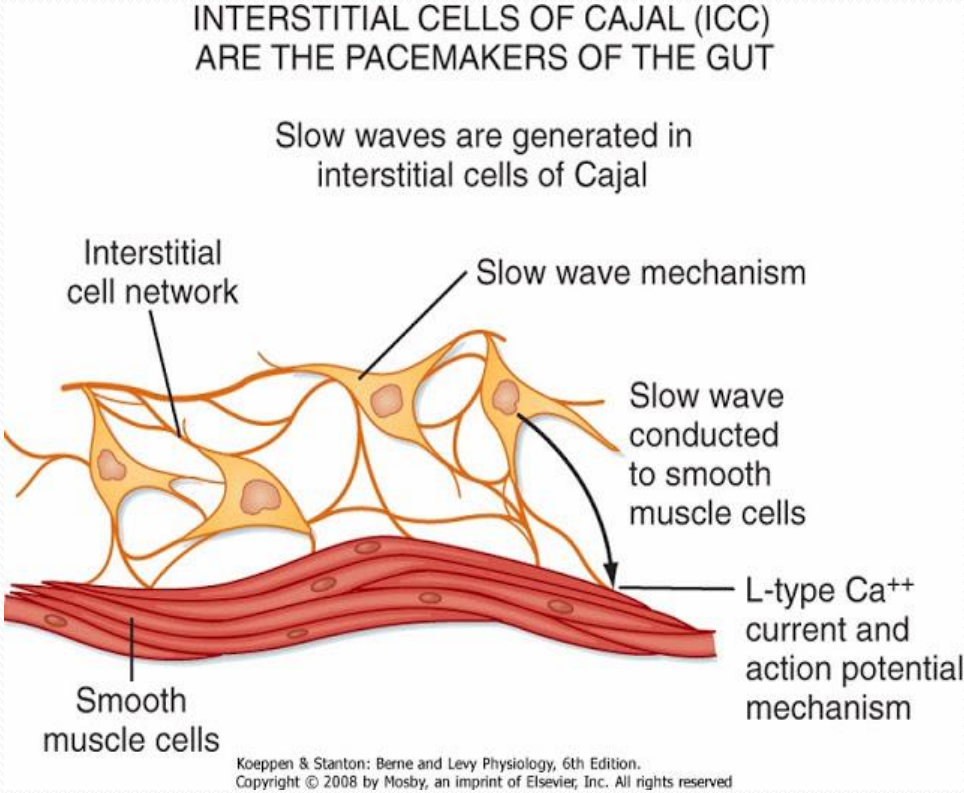

Motility Patterns and Measurement

- These include
  - non-propagating and
  - propagating pressure waves.
- Non-propagating- pressure waves occur randomly for at least 30 s.
- Occur simultaneously at least 10 cm apart with an onset time of <1 s.
- The function is not well delineated-
  - Mixing .
  - Mucosal sampling .

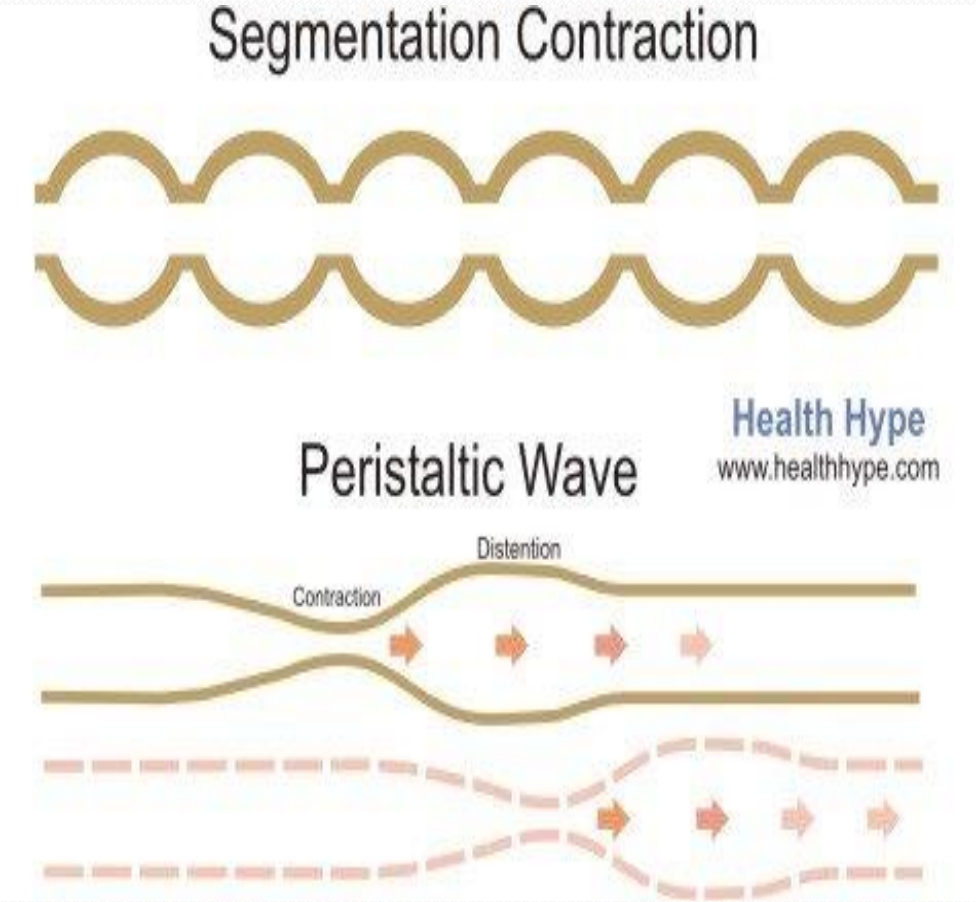

Propagating pressure waves and contractions

- serve to propel the colonic contents.

- Propagating pressure waves migrate -
  - ≥10 cm
  - at a velocity of 0.5 cm/s and
  - high amplitude propagated contractions (HAPC) of pressures ≥75 mmHg and that migrate aborad ≥15 cm.
- HAPCs-
  - approximately 6 /day and
  - serve to move stool across the colon.
  - Frequently, occur prior to defecation.

Figure 26.2

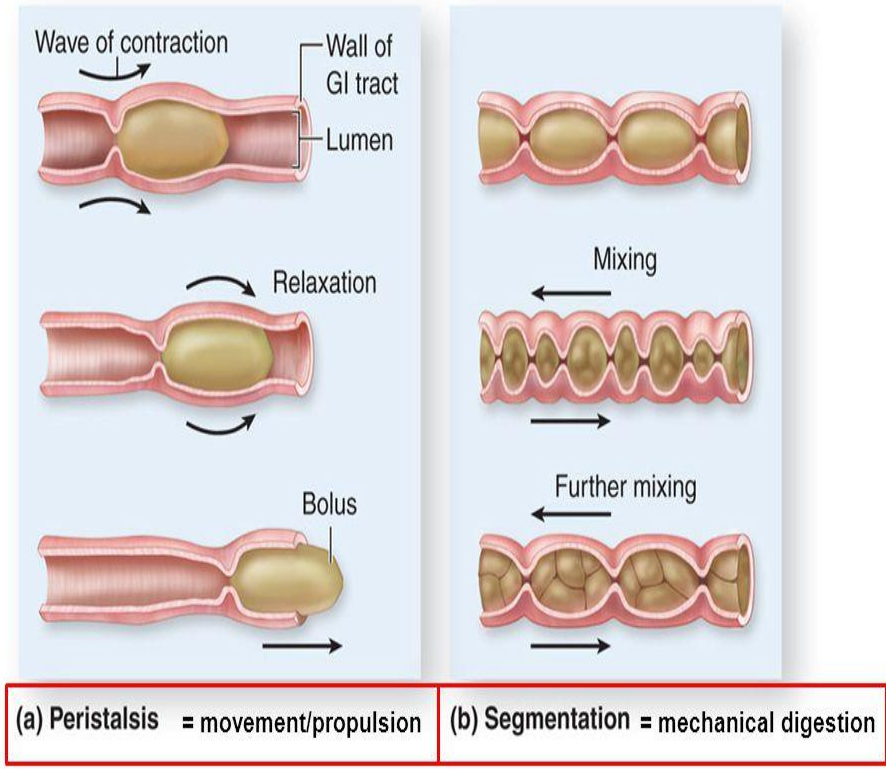

Patients with STC have a

- reduced frequency of HAPCs.
- lack of normal phasic response to meal.
- diurnal variation of colonic motor activity also may be abnormal.
- Colonic bisacodyl administration also produces a blunted HAPC response .

Altered colonic motility

- May manifest as constipation.

Figure 26.2

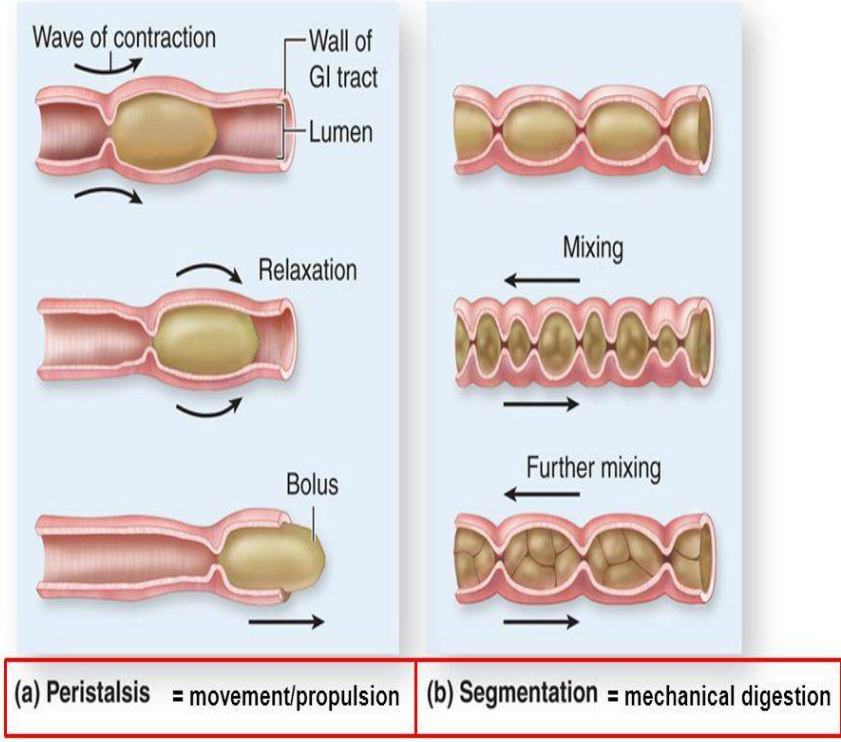

Transit time

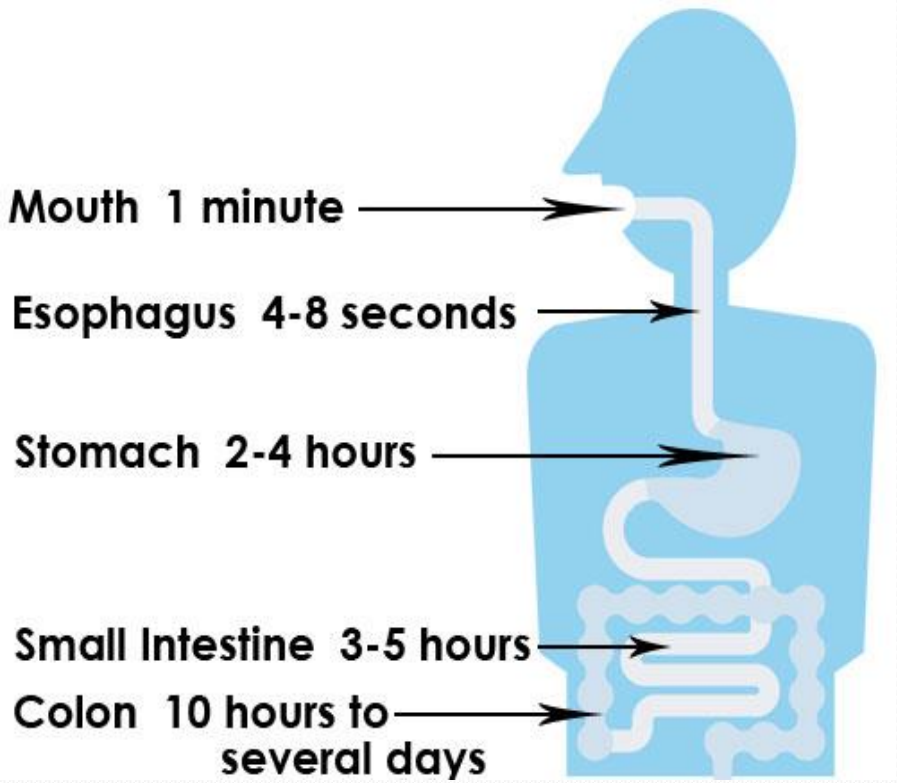

STC

Slow transit constipation - Signs and Symptoms

- Large soft stools
- Frequency 3 per week to 1 per 3 weeks
- Abdominal distention
- High incidence of faecal incontinence
- Symptoms of severe constipation within a year

Diagnostic Testing-

Initial laboratory testing for slow transit constipation should include—

- CBC,
- Calcium level, and
- Metabolic abnormalities -DM, hyperparathyroidism, or hypothyroidism.

- Colonoscopy- to rule out a mechanical obstruction from malignancy or strictures related to diverticular disease or inflammatory bowel disease.
- CTT
- Anorectal manometry testing, and
- Defecography.
- Dynamic MRI.

.

Anorectal Manometry

Aim:

Functional assessment of the anal sphincters and distal rectum.

Procedure:

- Microtransducers----in anal canal.
- Multichannel water perfused catheters .
- Flow rates of 0.3 ml / channel / minute .
- The resistance of flow of fluid from the catheter determines pressure measurements.

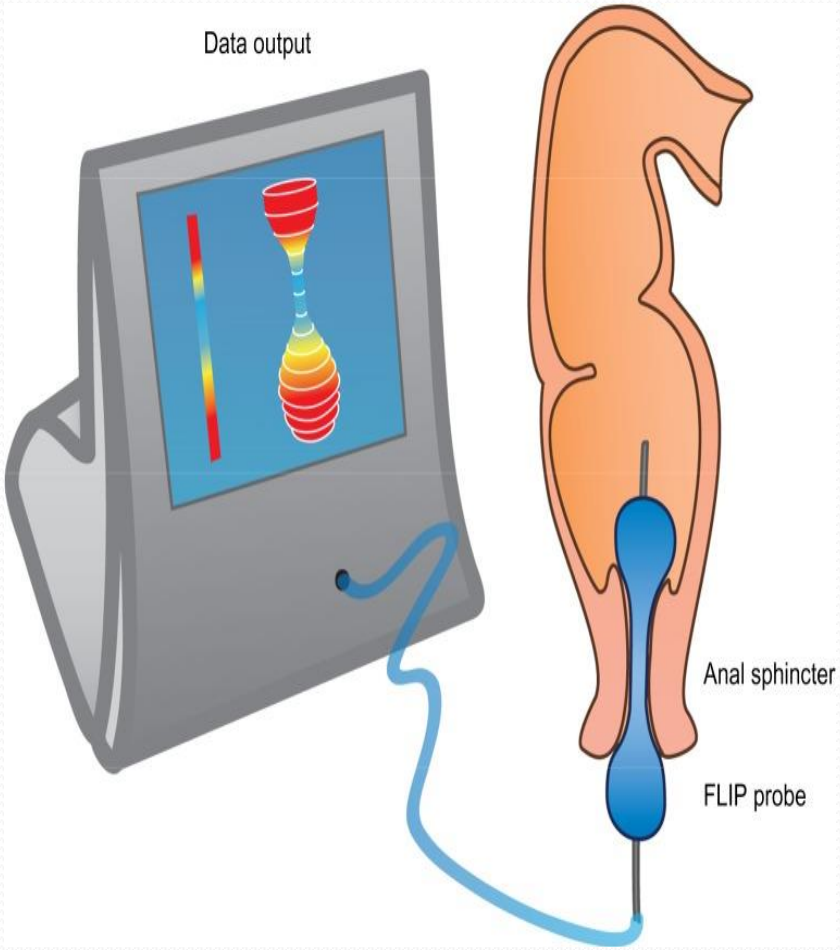

Anal Manometry

- RAP
- Squeeze pressure.
- High pressure zone.
- RAIR- absent in HD.
- Rectal sensation.
- Rectal compliance.

Balloon expulsion test-

- Main aim to identify-ODS.
- Normal pt can expel upto 50-150ml.
- Constipation, megarectum, nonrelaxing pelvic floor--cant expel even IRP is normal.

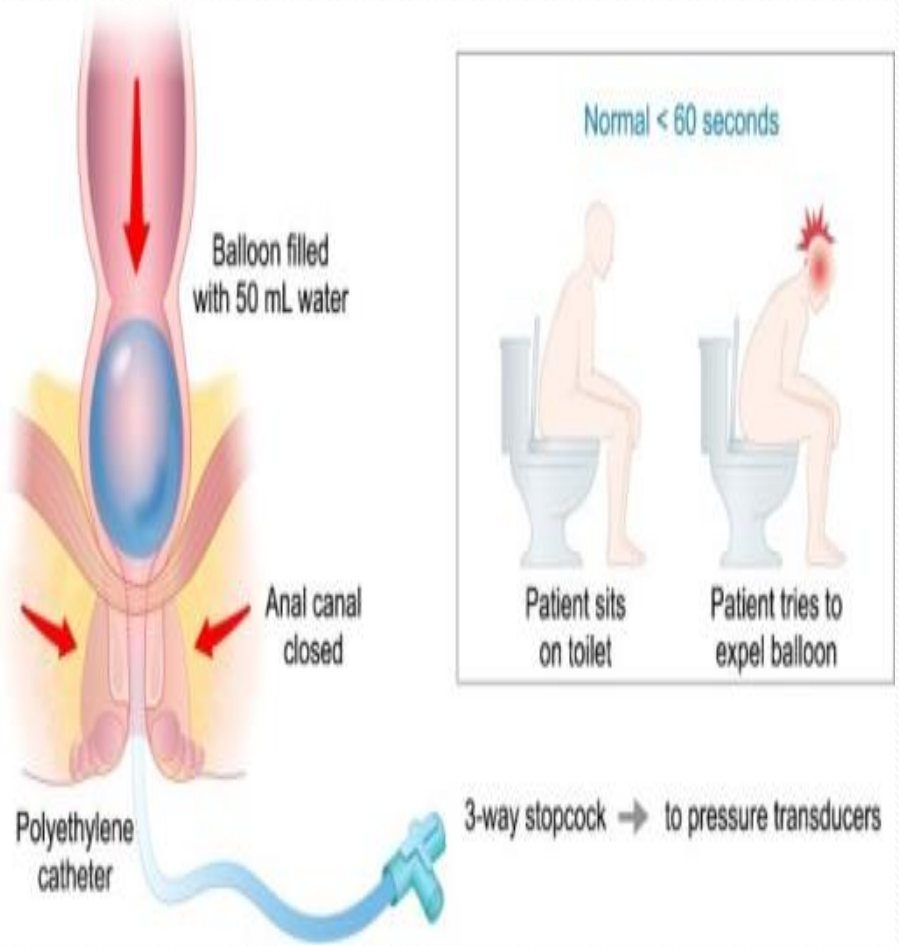

Defecography

Radiological visualization of the act of defecation.

Provides a picture –

- successive phases of defecation and
- dynamic impression of pelvic floor activity.
- Changes in the rectal configuration and the anorectal angle
- degree of evacuation.

Procedure:

- Contrast is inserted into the rectum and vagina, and
- Fluoroscopy is performed during defecation.

Defecography

Value in constipation–(indication)

- Paradoxical contraction of the pelvic floor- PFD
- Internal intussusception,
- Full thickness rectal prolapse,
- Rectocele, or enterocele.

Defecography serves 3 major purposes:

- preoperative evidence of presence and size,
- documentation of additional pelvic floor abnormalities
- objective assessment of postoperative changes.

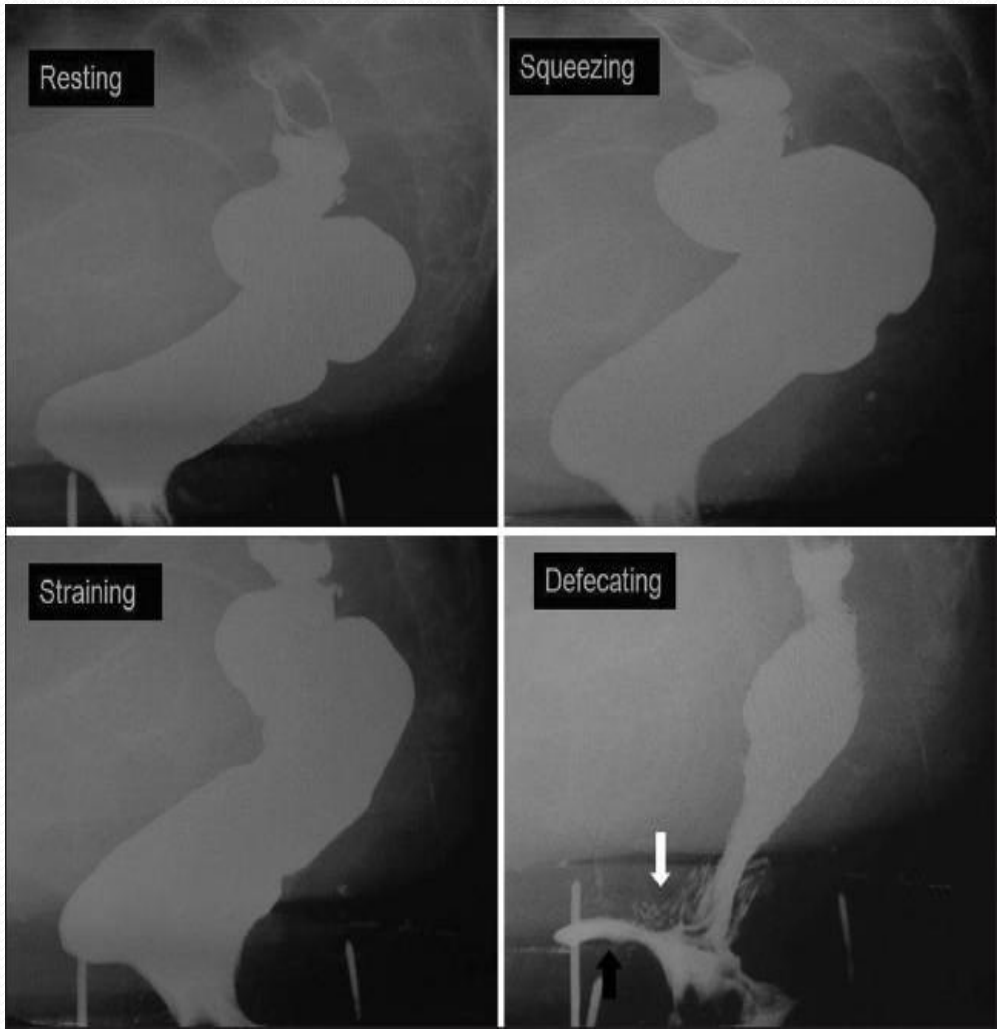

Dynamic MR defecography

Dynamic evaluation of the pelvic floor.

Evaluation of the anatomy and function during

- rest,
- squeezing,
- straining, and
- evacuation.

Contrast: (usually sonographic gel).

Types:

- open configuration MRI unit-
  - sitting during investigation,
  - superior
- closed-configuration units.

Limitations:

- expensive & not available in most institutions.
- Image quality- inferior in open-configuration units.
- closed unit MRI- in a supine position- not physiological.

Advantages:

- No radiation
- dynamic picture.
- useful in preoperative planning .
- Better diagnosis-
  - rectal intussusception than conventional defecography and
  - mucosal prolapse from full-thickness intussusceptions.

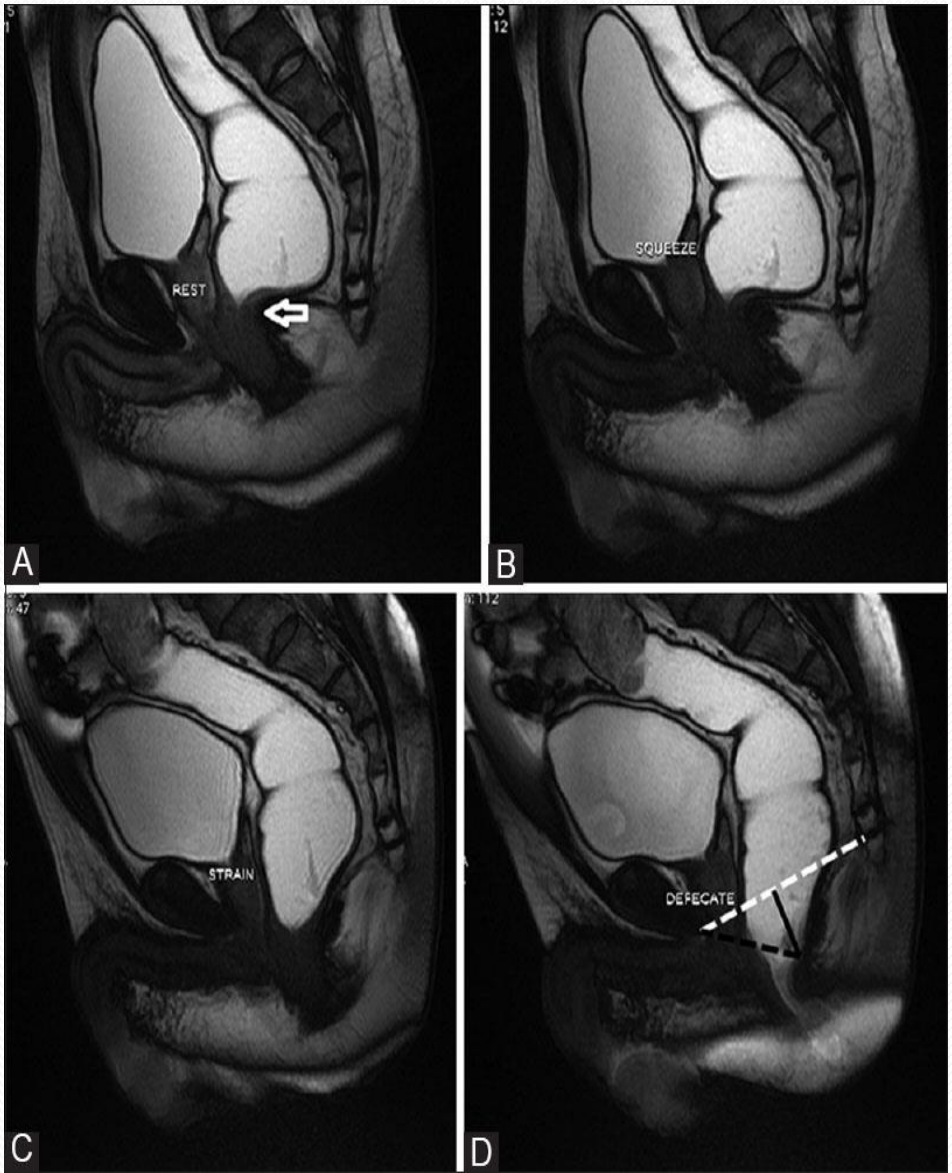

CTT

3 ways to assess transit time:

- radiopaque markers-most commonly performed.
- scintigraphy, and
- capsule studies

CTT

- Men- avg- 30.7 hrs
- Women-avg- 38.3 hrs.

Prerequisite-

- Cessation of all laxatives, enemas 48 hrs prior to swallow the markers.

Procedure-

- Several procedural variations.
- However, most often ingestion of Cap containing 20 markers-after 5 days abd. X-ray-evacuation 80%(14)- normal. Retention >20%(6)-STC.
- Commercially available cap(24)-on Sunday evening- x-ray on day 1,3,5-1st day-gastric/ SI normal if all markers within colon—normal study if >80% passed in day 5.
- Single cap(24) on 3 successive days-x-ray on 4th day-nb. Of markers=colonic TT in hrs.
  - Accumulation of markers in rectosigmoid - pelvic dyssynergia.

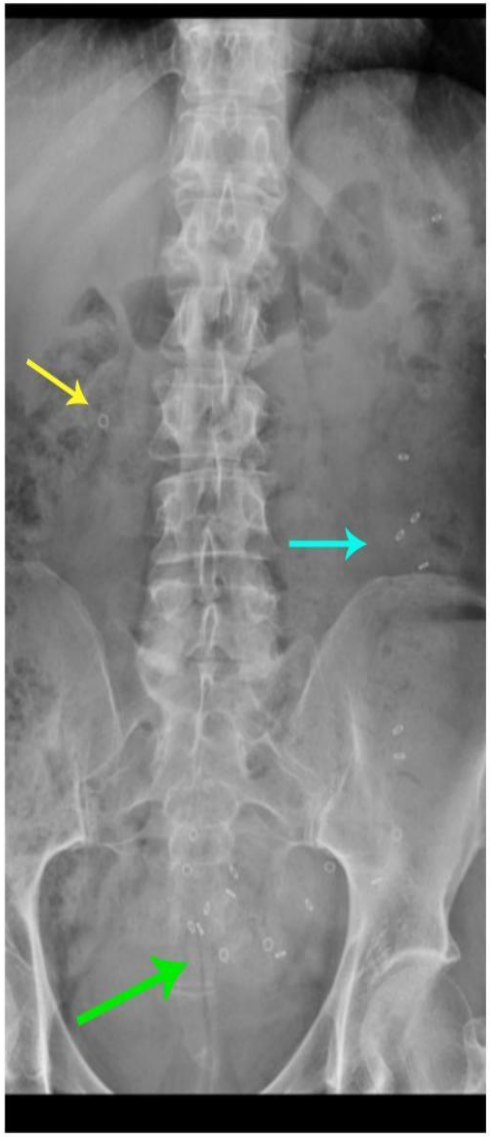



A. If 5 or fewer markers remain, patient has grossly normal colonic transit.

B. Most rings are scattered about the colon. Patient most likely has hypomotility or colonic inertia.

C. Most rings are gathered in the rectosigmoid. Patient has functional outlet obstruction.

Colonic Scintigraphy-

- Ingestion of an isotope (indium 111 or technetium 99) in a coated capsule or with a test meal.

- Gamma camera images are obtained and transit times are generated by following the passage of the isotope through the intestinal tract.

  - Reliable,
  - Costly
  - availability limit use.

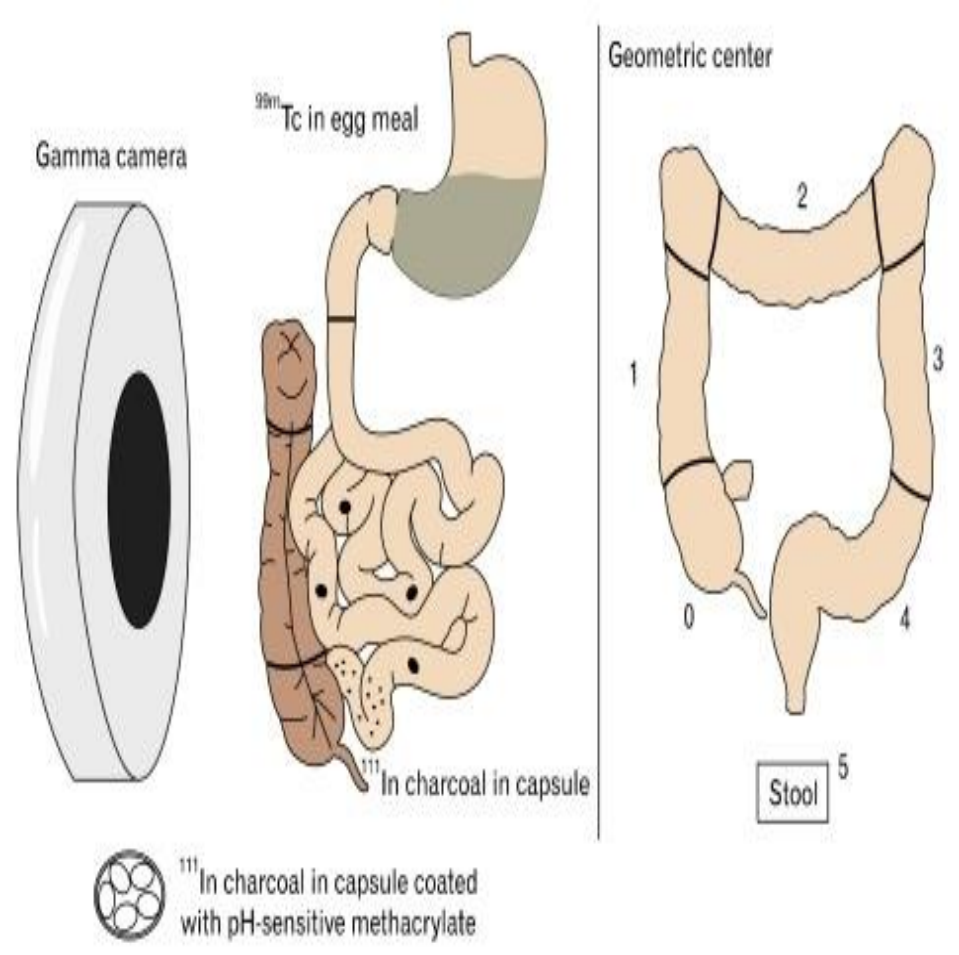

Wireless Motility Capsule

- Newer technology which allows for measurement of-
  - gastric,
  - small bowel, and
  - colonic transit times using *pH change and temperature*.

Good sensitivity and specificity.

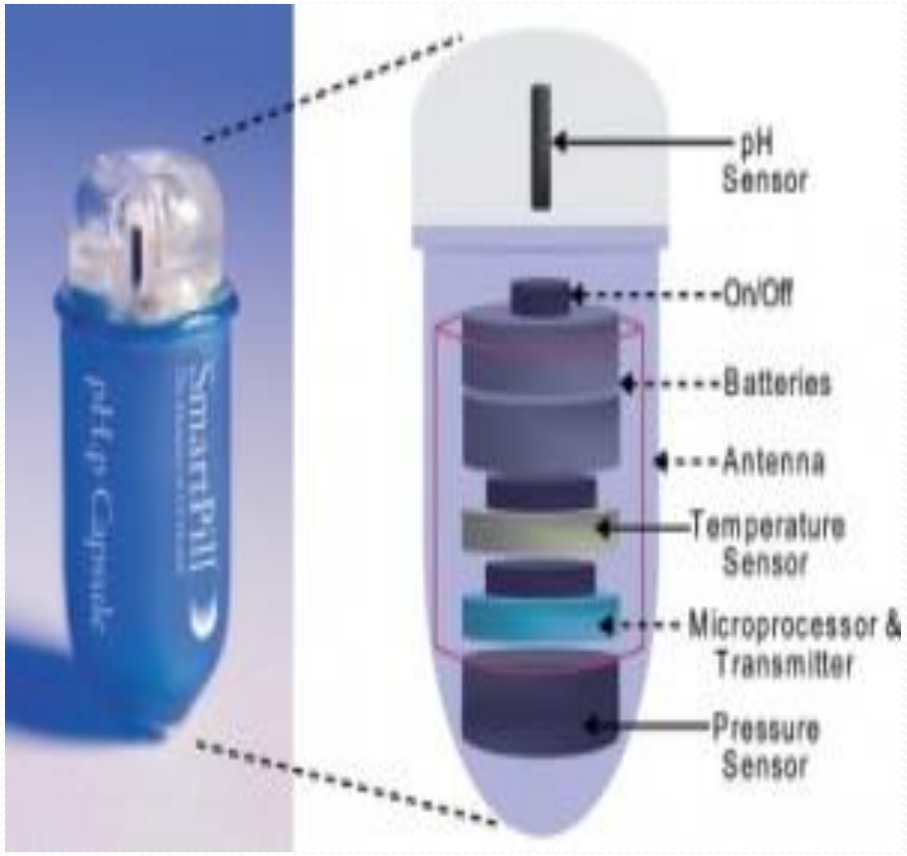

Irritable Bowel Syndrome

Functional disorder with multiple manifestations:

Constipation -predominant (IBS-C)-1/3rd pt.

- Women---primarily affected.
- Majority normal colonic transit and motility , although there is a possible overlap with STC.

Diarrhea -predominant (IBS-D)- 1/3rd of pt.

- Majority men .
- urgency and fecal incontinence.
- May follow acute gastroenteritis, pelvic surgery, or emotional stress.

Mixed (IBS-A).

C/F-

- altered bowel habits
- chronic, recurring abdominal pain .
- Extracolonic-
  - LBP,
  - lethargy, nausea,
  - urinary symptoms,
  - dyspareunia, and Dysmenorrhea.

TABLE 1.

Rome III Diagnostic Criteria for Irritable Bowel Syndrome

Criteria	Symptoms
1. Abdominal pain or discomfort accompanied by at least two of the following symptoms 25% of the time:*	A. Improvement with defecation. B. Onset associated with change in frequency of stools. C. Onset associated with a change in form (appearance) of stools.
2. No evidence of an inflammatory, anatomic, metabolic, or neoplastic process that explains the symptoms	

**Symptoms should be present at least once a week for 2 consecutive months.*

Aetiology-

- Unclear.
  - visceral hypersensitivity to intraluminal stimuli.
  - Aberrant motility, inflammation, anomalies in extrinsic autonomic innervation,
  - abnormal brain–gut interaction, and
  - psychosocial factors .
  - Hormonal --often increased perimenstrually.

Treatment- on the nature and severity of symptoms.

- Education,
- reassurance
- elimination of foods that incite symptoms.
- Sometimes fiber exacerbates the IBS.

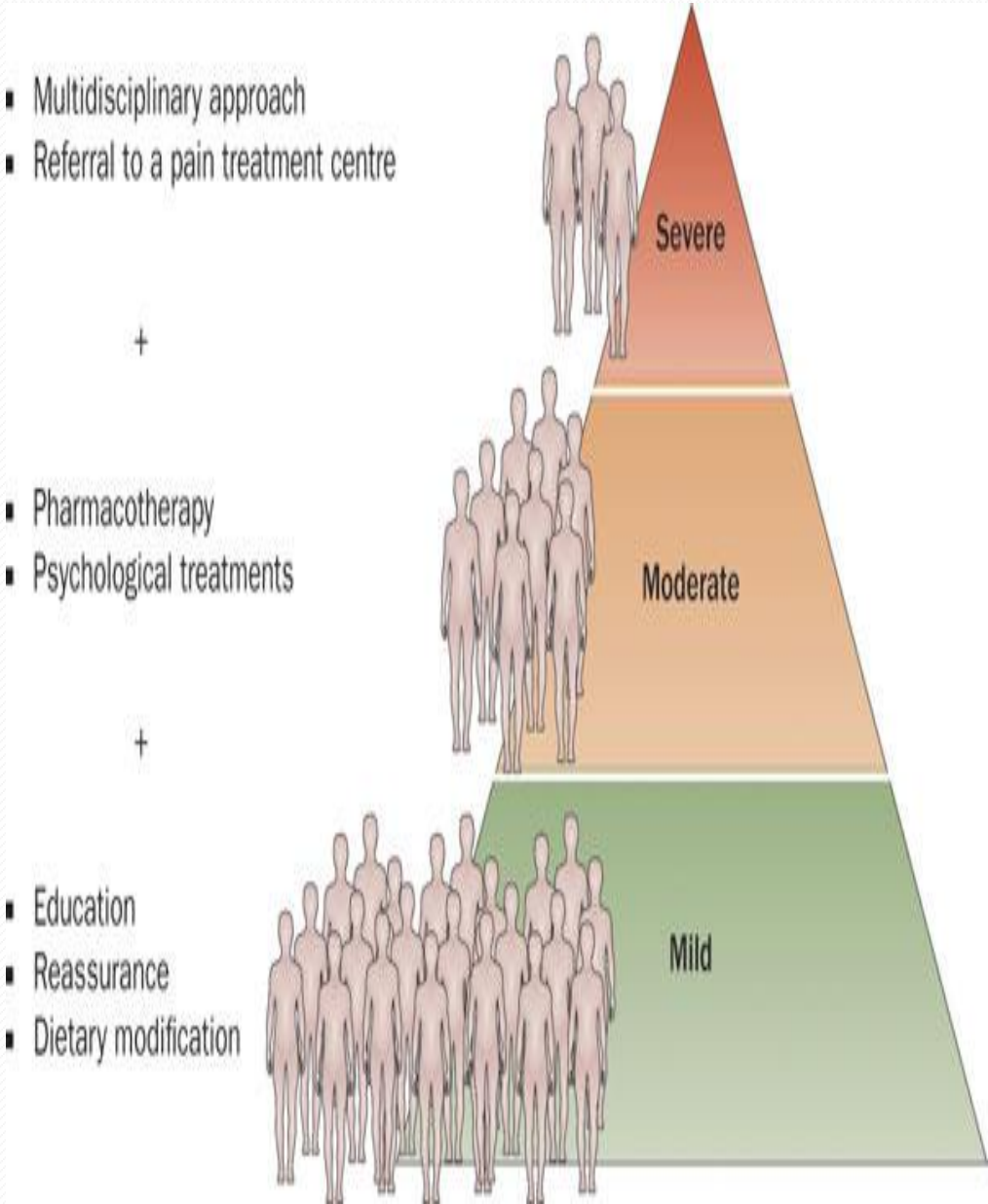

Who do not respond to conservative measures,

- medication is considered.
- Tegaserod--5-HT4 agonist a treatment of IBS-C but was withdrawn by the FDA due to a high incidence of MI, stroke, and unstable angina.
- In some studies, probiotics such as *Lactobacillus* and *Bifidobacterium produce variable degrees of* alleviation of IBS symptoms such as pain.
- Lubiprostone a prostaglandin E1 analog, activates type 2 chloride channels on the apical membrane of colonic epithelial cells.This medication promotes intestinal fluid secretion and, indirectly, colonic motility in patients with IBS-C.

IBS-D

Pathophysiology:

- accelerated proximal colonic transit,
- increased frequency of high and low amplitude propagated contractions.
- motor response to eating is enhanced --- intense urge to defecate and abdominal pain immediately after meals.
- Rectal hypersensitivity .

Treatment:

- Antispasmodics—eg. hyoscine for pain and bloating.
- Low-dose TCA(e.g.,amitriptyline) when pain is more constant and disabling; function not as mood stabilizers but instead act directly on the gut and central pain processing.
- Loperamide - safe for long-term use.

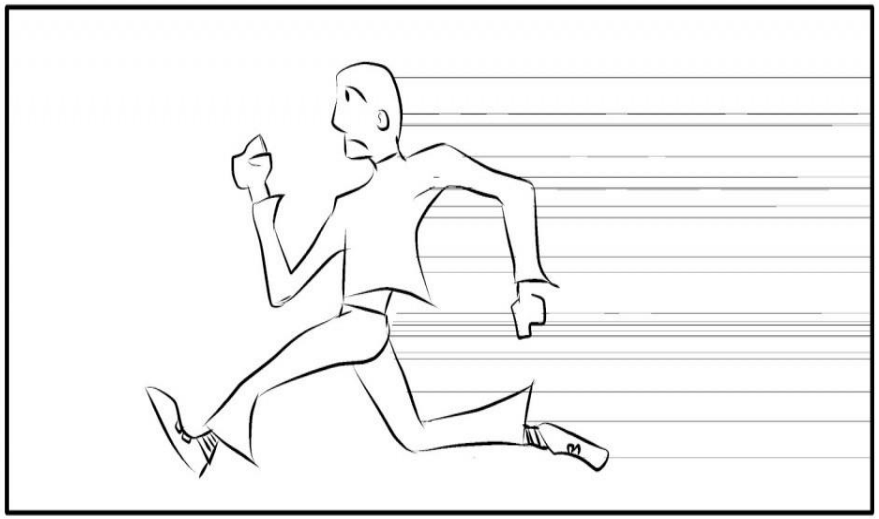

IBS explained in pictures

- Majority men .
- urgency and fecal incontinence.
- May follow acute gastroenteritis, pelvic surgery, or emotional stress.

Hirschsprung's Disease

Functional partial colonic obstruction due to the absence of ganglion cells.

- Approximately 1 in 5,000 births.
- Boys- (80%-BL)

Pathophysiology:

Failure of migration of vagal neural crest cells into developing gut---Absence of ganglion cells in myenteric & Meissner's plexus ---lack of relaxation cause partial colonic obstruction.

Classification:

- Short segment: Most common ,includes the rectum and most of the sigmoid colon. Nearly 80%.
- Long segment: Approx. 10% & extends up to splenic flexure or upper descending colon.
- Total colonic aganglionosis - in 8–10%. sometimes extend to the distal terminal ileum.
- Ultra short" aganglionosis- only a few cm above the pectinate line.
- Very rarely universal aganglionosis- entire GIT.

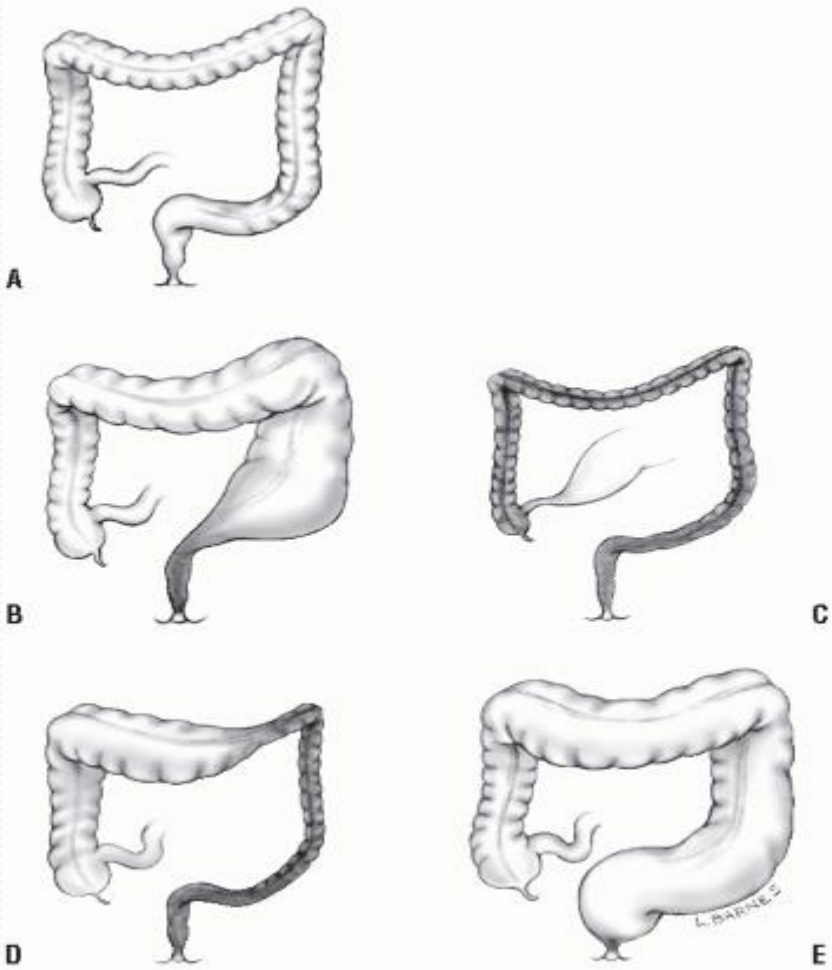

Dangers:

- Poor immunologic mucosal barrier------- enterocolitis, main cause of death.
- Fecal stasis---production of endotoxins.

Genetics: may be familial or associated with Down's syndrome or other genetic disease.

- Mutations on chr. No. 10 & 13 in some patient.

Clinical manifestations—

- Usually symptomatic during the 1st 24–48 h.
- Delayed passage of meconium (>24 h),
- Abdominal distention, and
- Bilious vomiting - most common symptoms.

DRE:

- Narrow empty rectum above which faecal impaction
- DRE follows gush of faeces & flatus

Abdominal film- massive dilatation of small bowel and colon.

Contrast enema: nondilated aganglionic segment of the rectosigmoid, followed by a transitional zone and then a proximal dilatation.

The definitive diagnosis by a rectal biopsy—

- absence of ganglion cells, and
- presence of hypertrophic nerves.

- Full-thickness under direct vision, or a suction biopsy --specimen must include mucosa and submucosa.

Complications:

If the colon is not decompressed-

- sepsis,
- hypovolemia,
- endotoxic shock
- Cecal perforation.
- who survive without treatment, ultimately develop the classic clinical picture-
  - severe constipation,
  - huge megacolon, and
  - enormously distended abdomen

Diagnosis

- Abdominal plain X-rays
- Barium Enema
- Rectal Biopsies
- Anal manometry

Differential diagnosis:

Idiopathic chronic constipation-

- Pt not seriously ill,
- Overflow incontinence (encopresis).
- DRE: rectum full of fecal matter.

Hirschsprung's disease suffer from

- malnutrition, and
- lack of normal development.
- empty, aganglionic, and narrow rectum and they do not suffer from soiling.

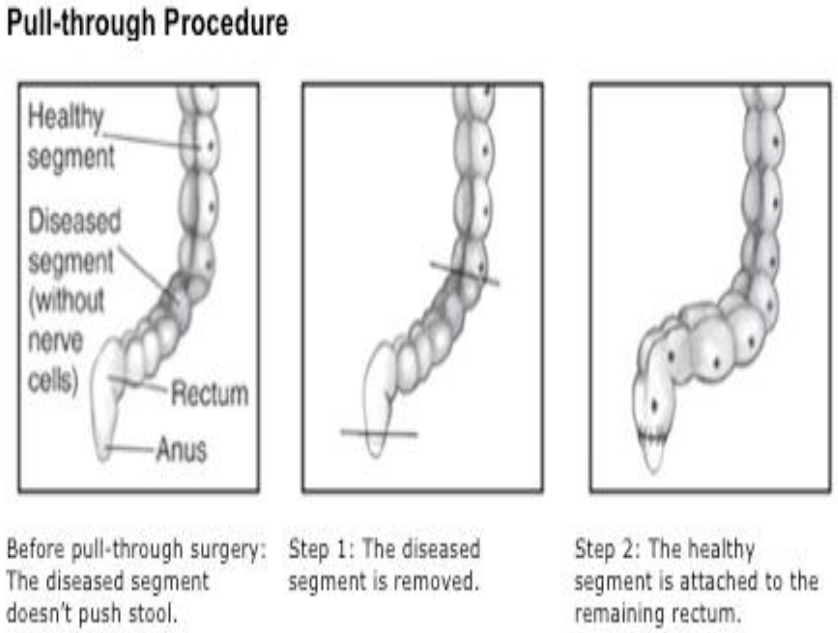

Medical Management-

- Colonic decompression and irrigation with NS--for emergency management.
- After histologic diagnosis--surgical treatment.

Surgical Treatment

Principal:

resection of the aganglionic segment and pull-through of a normoganglionic segment to anastomose just above the anal canal, immediately above the pectinate line.

- 1st stage--diverting colostomy, usually in the transverse colon.
- 2nd stage-- resection of the aganglionic segment and pull-through of the normoganglionic bowel.
- 3rd stage--colostomy closure.

Two-stage- opening of the colostomy at the level of the ganglion cells. The second stage consists of pull through, leaving the patient without a colostomy.

More recently- neonatal primary procedure without a protective colostomy.

Surgery

Swenson and Bill operation-

- resection of the aganglionic & part of the normoganglionic dilated colon, and coloanal anastomosis above the pectinate line.

Duhamel operation -preserve the aganglionic rectum, normoganglionic colon is then pulled through a presacral space, & anastomosed to the rectal wall above the pectinate line.

Soave procedure-

- endorectal (submucosal) dissection leaving a seromuscular cuff carried down to the rectum above the pectinate line. The normally innervated colon is passed through the muscular cuff and anastomosed to the rectum.
- Most commonly chosen technique worldwide.

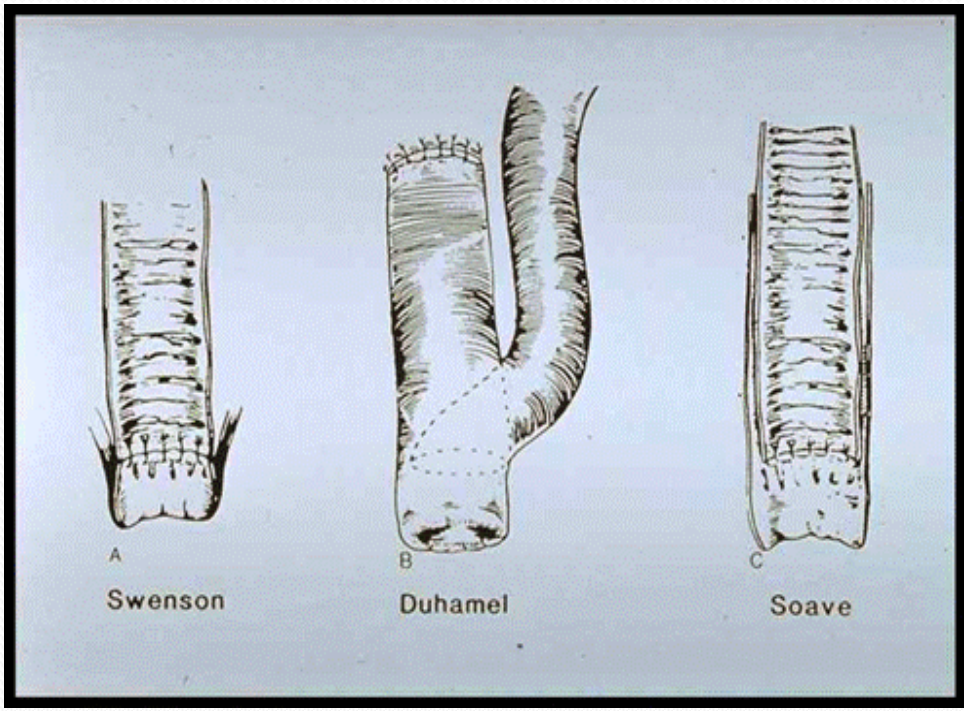

ODS

The cardinal symptoms-

- straining at stool,
- sense of incomplete evacuation,
- Rectal, vaginal or perineal digitations.
- Paradoxical contraction of the puborectalis during straining -PFD.
- psychological problems.

Causes-

- Rectocele, enterocele, sigmoidocele.
- Intususception
- SRUS
- Perineal descent.
- Pelvic floor dyssynergia

Anismus / dyssynergic defecation / spastic pelvic floor syndrome

Failure of normal relaxation of pelvic floor muscle during attempted defecation.

- In both childrens & adults.
- > in woman.

Functional defecation disorder / functional rectal outlet obs---constipation----ODS.

S/S-

- Straining to defecate.
- Tenesmus.
- Feeling anorectal obs.
- Digital evacuation of stool.

.

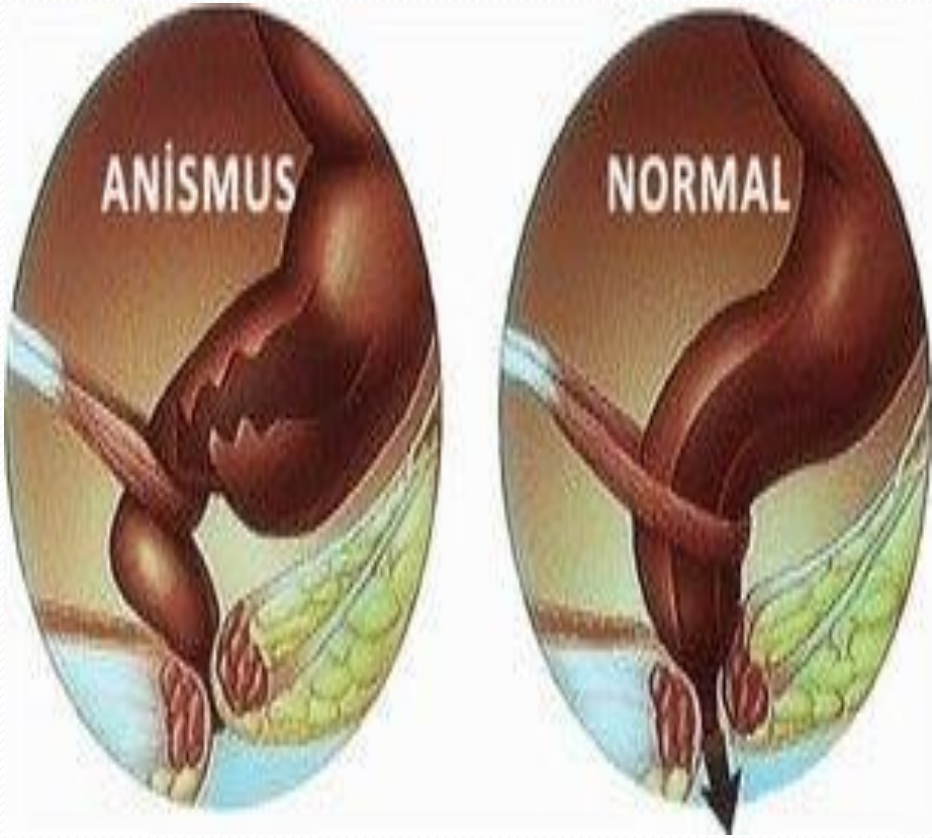

Diagnosis-

DRE- dyssynergic contraction and relaxation during defecation.

Balloon expulsion test-

- Main aim to identify-ODS.
- Normal pt can expel upto 50-150ml within 1 min.
- Constipation, megarectum, nonrelaxing pelvic floor--cant expel even IRP is normal.

- Manometry
- Defecation proctography
- MR defecography

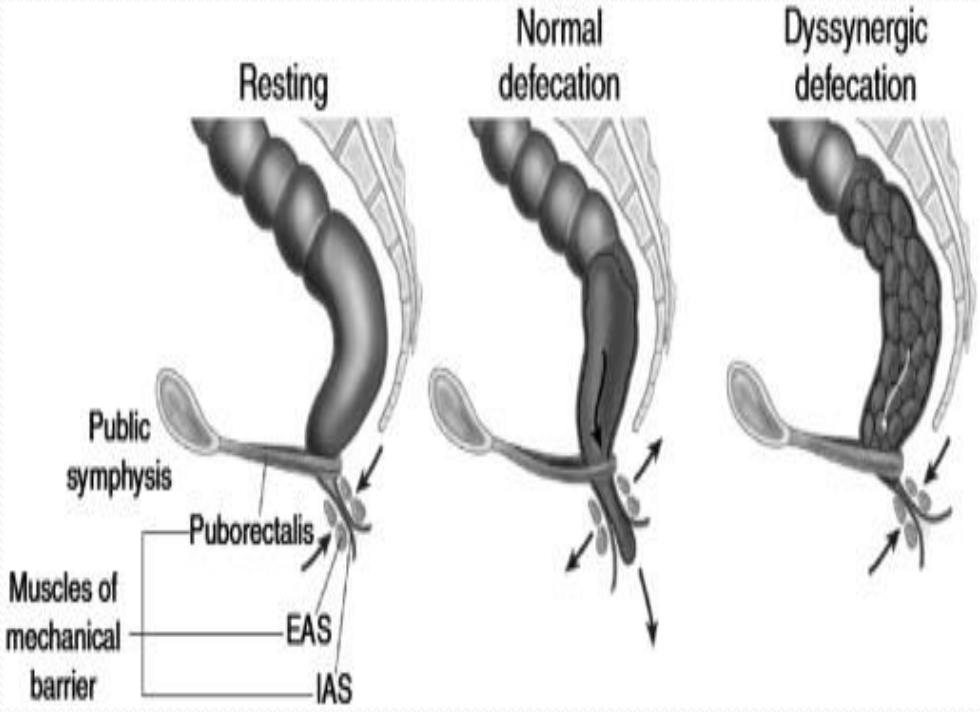

Colonic inertia

Severe functional colonic motility disorder causing significant disability of the patient.

- Majority present since childhood.

Pathology-

- Ineffective colonic propulsion.
- Failure of meal / stimulant to enhance colonic phasic contraction.

S/S-

- Abdominal distension.
- Infrequent defecation
- Abd. Pain , bloating.
- Incomplete evacuation.

IX-

- CTT
- Manometry
- Antroduodenal manometry.

Management

Outcome varies for colonic inertia with-

- Pelvic floor function.
- Colon motility
- STC with widespread GI inertia.

Medical MX-

- Dietary fibres
- Laxatives, Suppossitories
- Enema
- Novel prokinetics.

Surgical Mx-

- Total colectomy & IRA
- IPAA
- Permanent stoma-when all modalities fail.
- SNS
- Antegrade colonic enema.

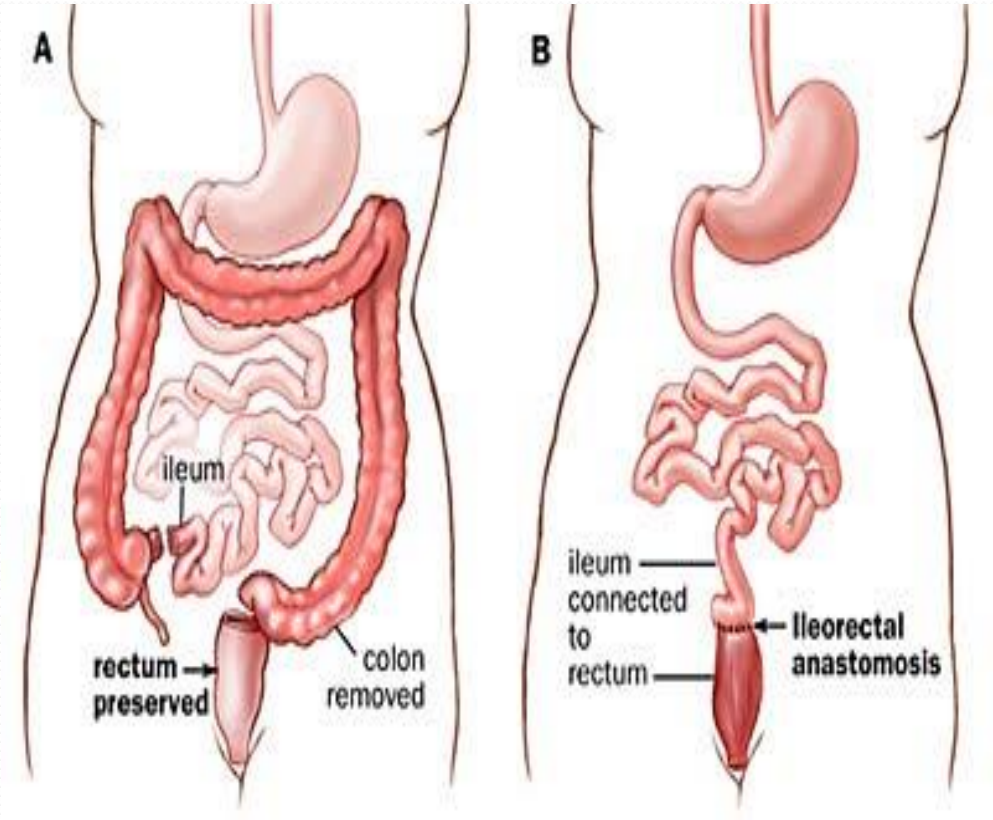

Pelvic Floor Descent/ Failure

Excessive perineal descent -

- FI,
- Severe constipation,
- SRUS,
- anterior mucosal and full-thickness rectal prolapse.
- Urinary voiding problem.

Pathophysiology:

- Abnormal perineal descent, during straining, ----traction and damage to the pudendal & pelvic floor nerves----neuropathy & muscular atrophy.

- Irreversible pudendal nerve damage occurs after a stretch of 12% of its length, and

- Descent of perineum of 2 cm, estimated to cause pudendal nerve stretching of 20%.

Diagnosis:

Precipitating factor :

- Chronic straining- 75% of subjects.
- Increased age
- Female.
- Neuropathy.
- **Chronic illness**
- **Malnutrition**
- **Internal prolapse**
- **Genitourinary & rectal prolapse.**

O/E-

- Obliteration of perineal concavity- outward ballooning of perineum.
- Genital or rectal prolapse.

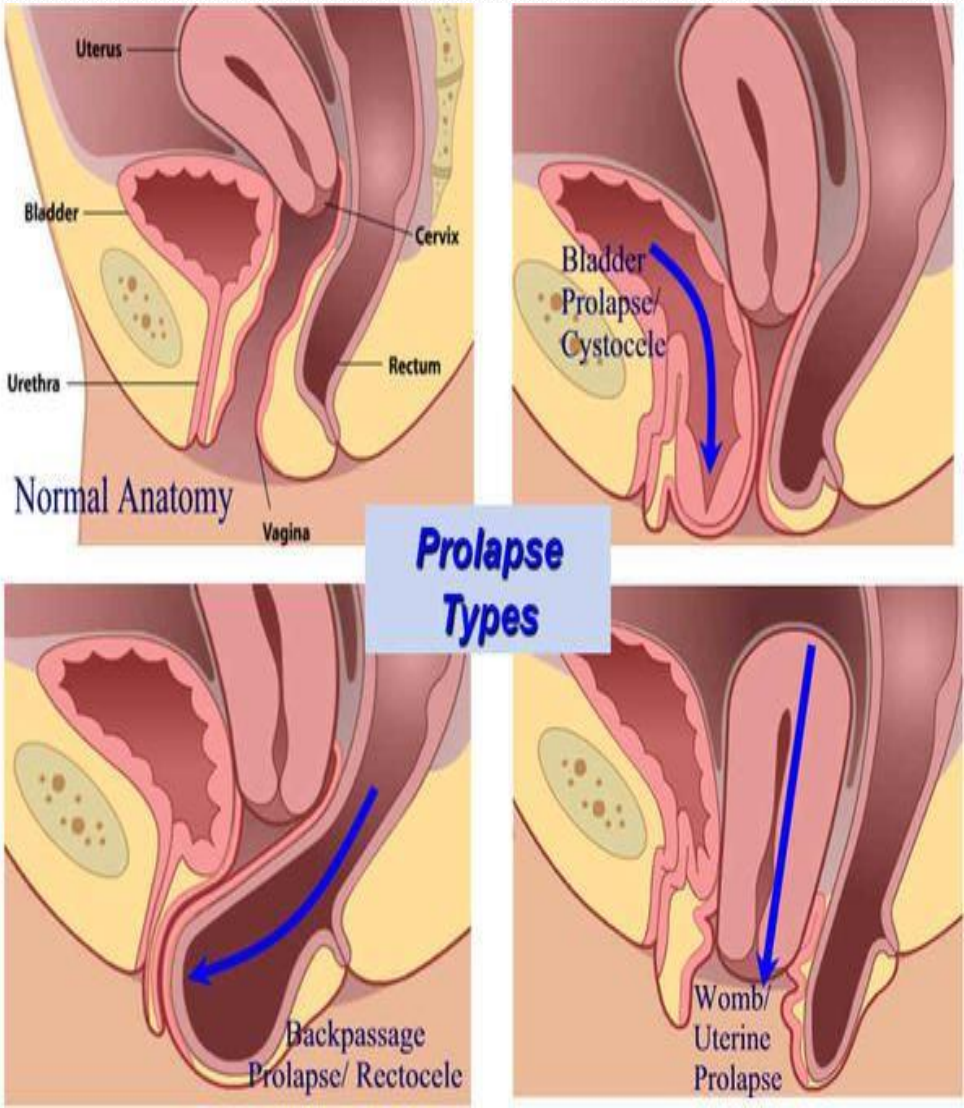

Investigation:

St Mark's perineometer placed on the ischial tuberosities---movable latex cylinder on the perineal skin----The distance between the level of the perineum and the ischial tuberosities is measured at rest & straining.

Interpretation:

- **Negative- plane** of the perineum is above the tuberosities .
- Positive- descent below this level.
- The plane of the perineum at rest should be −2.5±0.6 cm, descending to +0.9±1.0 cm on straining.

Dynamic proctography- The anorectal angle normally lies on a PCL & descends by 2±0.3 cm on straining.

- In DPS----descends 5-6 cm from PCL.

Management:

- Dietary fibre
- Laxative.
- Bowel training----avoid straining.

Surgery:

- Restoration of pelvic floor by mesh & suspension or resection of rectum.
- Combined- abd. Colporectopexy with obliteration of Cul De sac.
- Combined abdominoperineal approach -colporectopexy with plication of levator & ant. Perineorrhaphy.
- In pelvic floor laxity- cystocele rectocele enterocele-----total pelvic Marlex mesh repair.

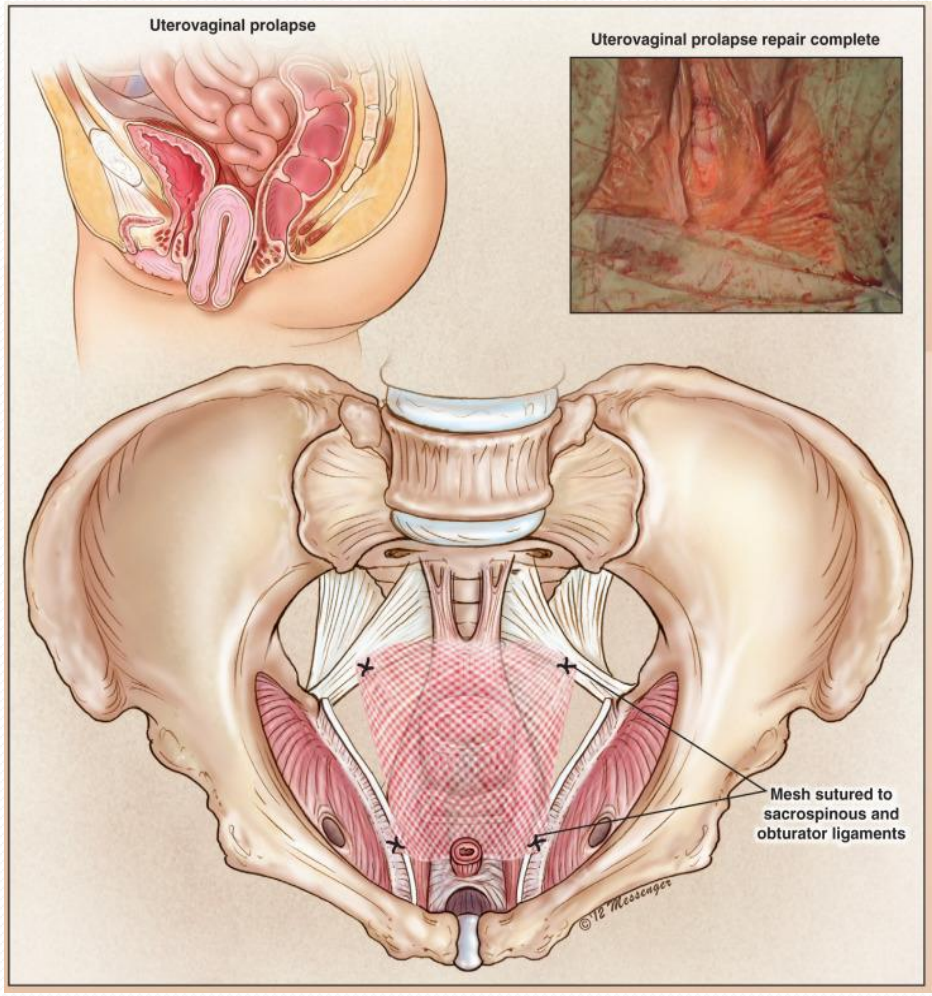

Solitary rectal ulcer syndrome

Diagnostic problem & can easily be confused with rectal cancer.

Aetiology: unclear, but a common feature is chronic inflammation &/or trauma result from -

- IBD.
- Resolving ischemia,
- internal intussusception
- Rectal prolapse
- direct digital trauma,
- Forces evacuating a hard stool.

Predisposing factors:

- Difficulty in defecation
- Straining & incomplete evacuation
- Increased intrarectal pressure
- anal digitation, and

-results in anterior mucosal trauma and ulceration.

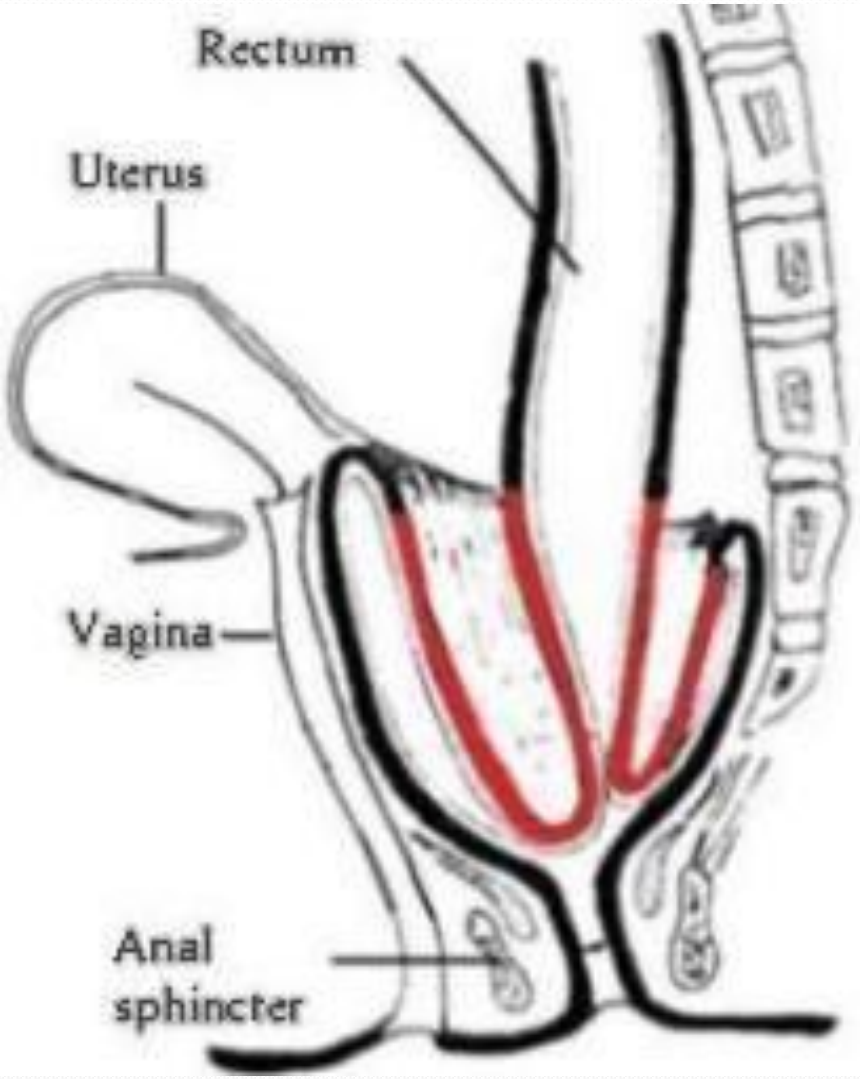

SRUS is characterized by –

PR bleeding,
copious mucous discharge,
anorectal pain, and
difficult evacuation.

Number: single, multiple, or no rectal ulcers.

Site: usually on the anterior rectal wall just above the anorectal ring (4-12 cm from anal verge).

Morphology: shallow with a “punched out” gray-white base surrounded by hyperemia.

Investigations:

- DRE-ulcer in the anterior rectal wall.
  - 2-3 cm in size.
  - single multiple or no rectal ulcer
  - Edge- punched out with gray white base surrounded by hyperemia.
  - Base- indurated.

Colonoscopy- in symptomatic patients.

Defecography is generally abnormal in most patients.

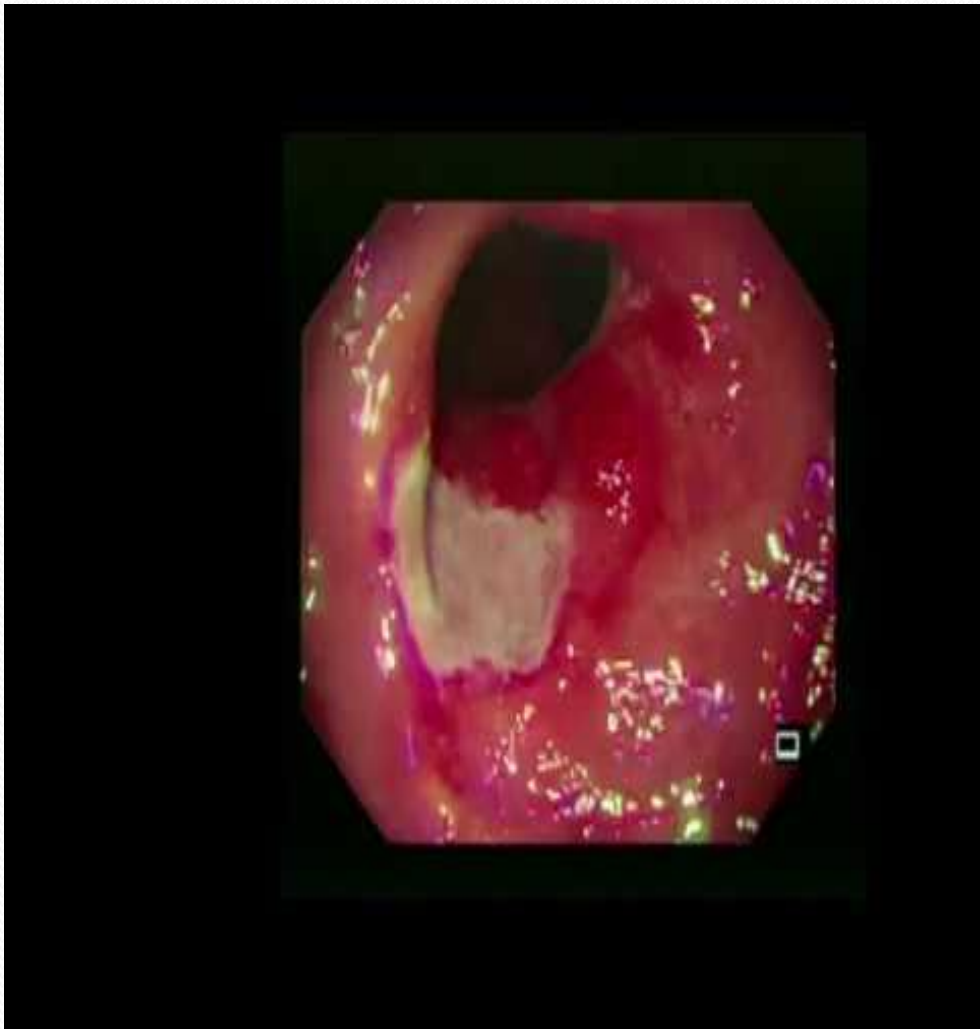

D/D-

endometriosis,
inflammatory granulomas,
Infectious disorders, drug-induced colitides, and adenocarcinoma.

Differentiation- by histopathology.

- Obliteration of the lamina propria by fibrosis and a thickened muscularis mucosa with muscle fibers.

Treatment—conservative therapy -first.

- Dietary changes,
- Bulking agents and
- Biofeedback .

- Surgery- rarely indicated
  - For prolapse or
  - Refractory to conservative management
- TAE of the ulcer,
- Stapled mucosal resection,
- Modified anterior delorme procedure,
- Abdominal rectopexy (rectal prolapse), and colostomy formation.

Result:

- Simple resection without biofeedback does not resolve the symptoms.
- Rectopexy---- high failure rates of up to 50%,
- Early results of STARR in refractory SRUS appear encouraging.

Rectocele

Herniation of the anterior rectal wall into the lumen of the vagina.

Pathogenesis:

- Chronic straining on a weakened rectovaginal septum both by-
  - obstetric trauma and
  - Progressive pelvic floor deficiency, as part of the aging process.
- Others believe that rectoceles ---ODS by trapping of feces---further straining --- aggravates the problem.
- 4th or 5th decade of life.

5 most common presenting symptoms---

- excessive straining,
- incomplete evacuation,
- manual assistance required,
- sense of fullness,
- Bowel movement <3/week.

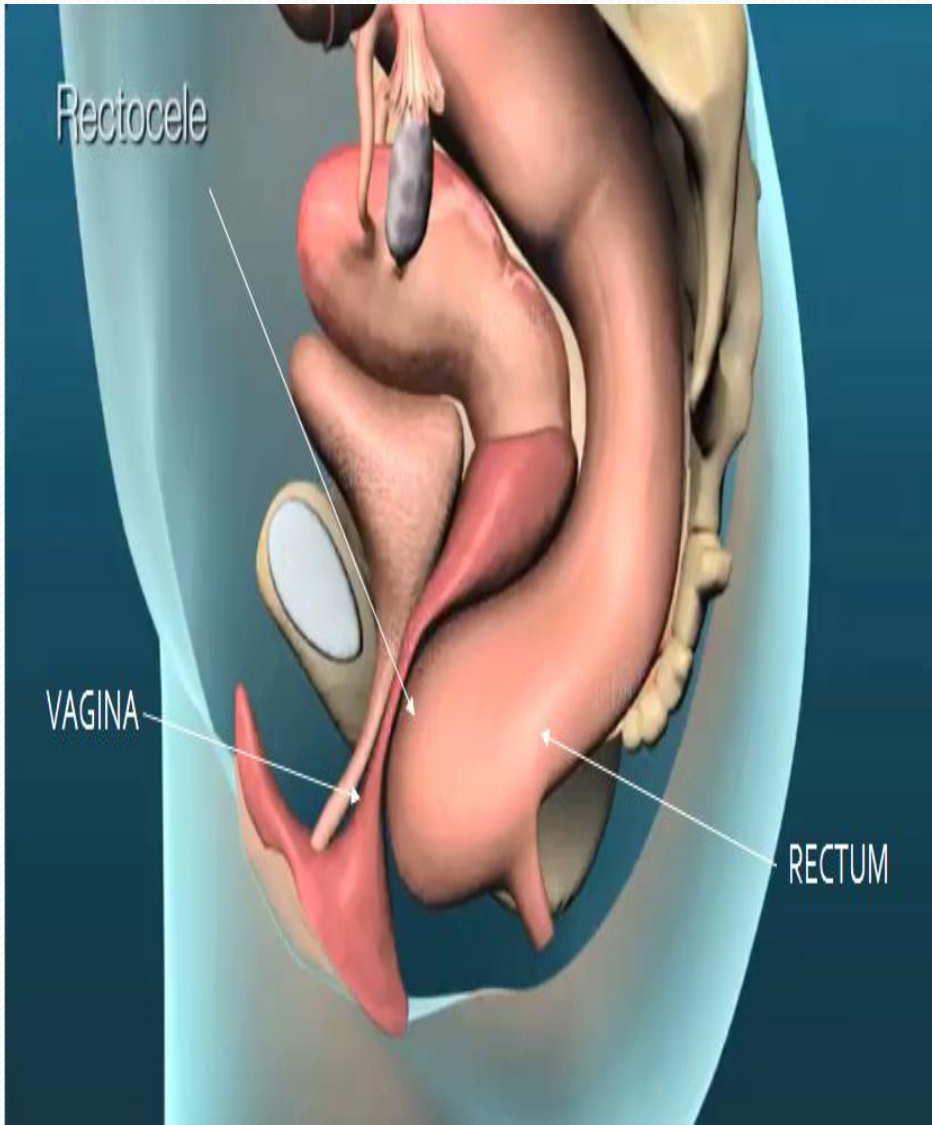

Diagnosis:

- adequate history
- bimanual or rectovaginal palpation.
- **A hooked finger -** pocket-like defect.
- Defecography- <2 cm=insignificant.
  - >3 cm in depth- abnormal.

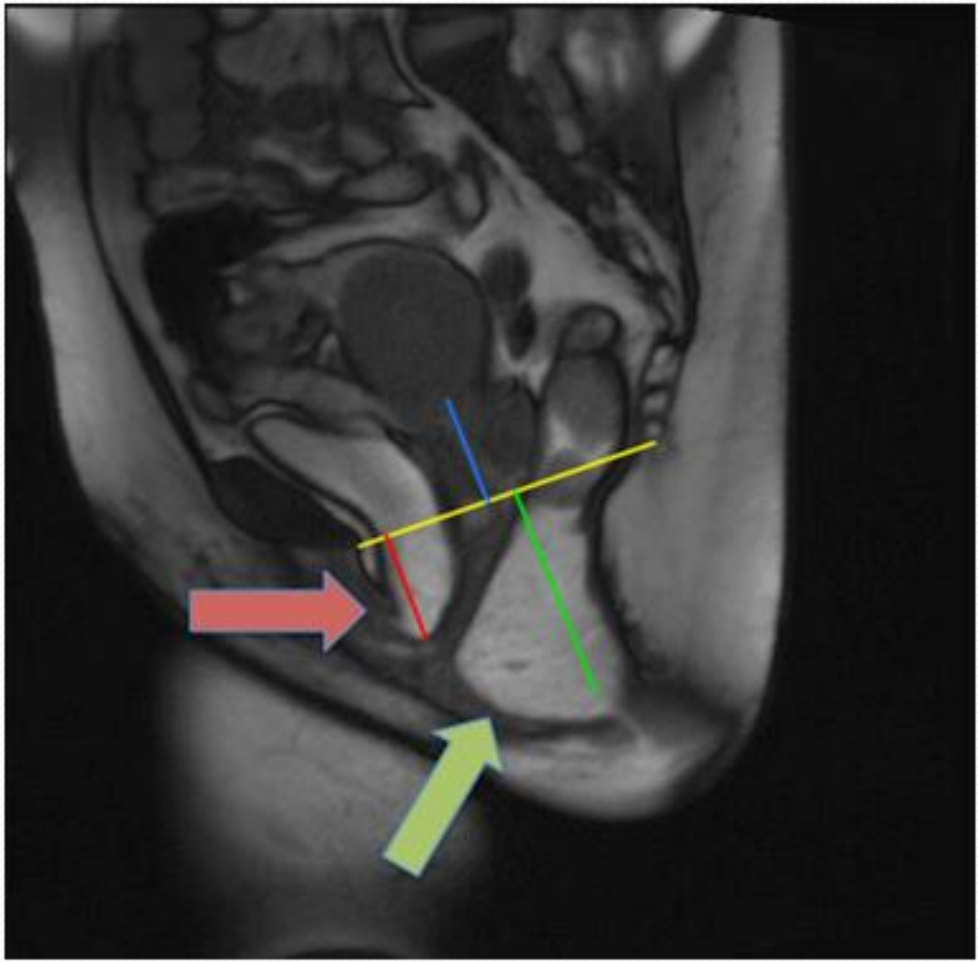

Investigation:

Defecography –

- Size,
- Barium trapping,
- Intussusception,
- evacuation, and perineal descent

Serves 3 major purposes:

- Preoperative presence and size,
- Additional pelvic floor abnormalities,
- Assessment of postop changes.

Rectocele Repair

- Transvaginal,
- Transanal
- Transperineal
- Abdominal.

Till now it is not known which treatment is the most optimal one.

Prognosis:

- Previous hysterectomy,
- Large rectal area on defecography,
- Preoperative use of enemas and laxatives related to a poor outcome.

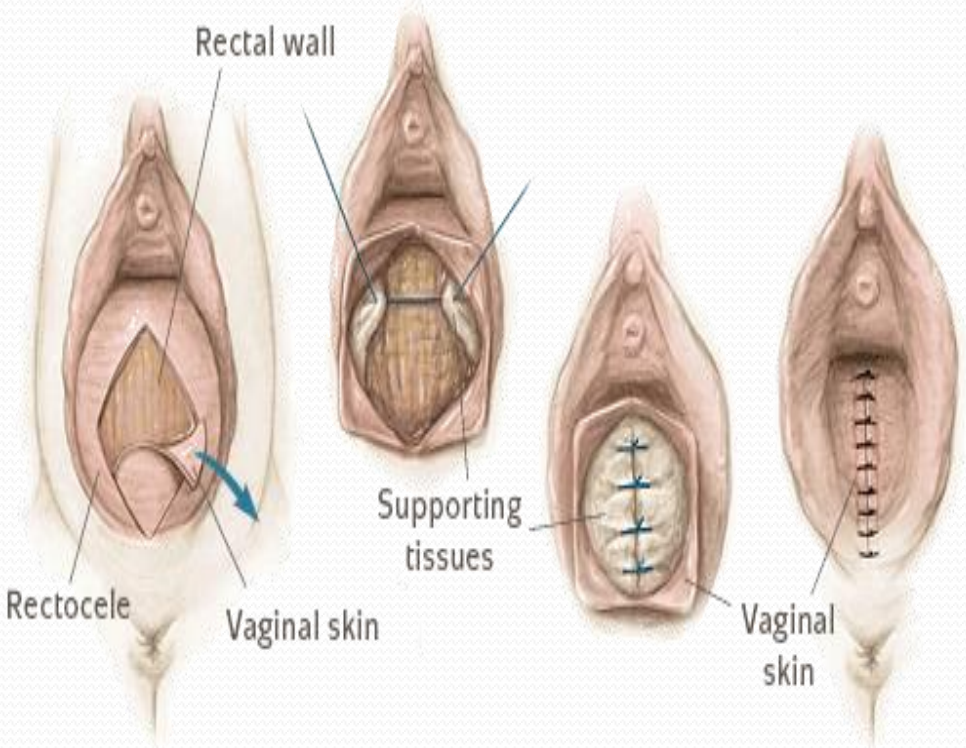

www.Ferdauscolorectalcare.info